

SPRING, 1989

VOLUME 20, NUMBER 1

FOCAL SPOT

MALLINCKRODT INSTITUTE OF RADIOLOGY



**FAMILY
MATTERS**

Property of Washington University
Medical Library APR 18 '89 ARCHIVES
Indiana



The newly completed offices on Mallinckrodt Institute's 12th floor overlook Forest Park and, to the west, downtown Clayton. Photograph by Ronald G. Evens, M.D.

FOCAL SPOT

SPRING, 1989

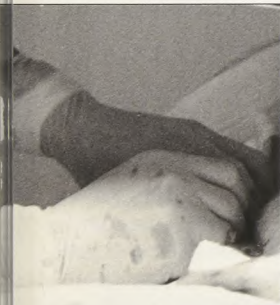VOLUME 20, NUMBER 1

MALLINCKRODT INSTITUTE OF RADIOLOGY



6 OVERCOMING INFERTILITY

A radiological approach helps women become mothers when blocked Fallopian tubes prevent conception.



12 FAMILY MATTERS

Millions of would-be fathers suffer varicoceles that cause infertility and pain; embolization is helping them.



18 MINIMIZING THE RISK

Research reveals the need for an implant that does not obscure breast tissue on a mammogram.



2 SPOT NEWS

23 FYI

28 SPOTLIGHT

MALLINCKRODT
INSTITUTE
OF RADIOLOGY
GEORGETOWN UNIVERSITY MEDICAL CENTER

ON THE COVER:

Infertility—in one of its many forms—blocks the path to fulfillment for one in six U.S. couples of child-bearing age. But radiology is leading the way in revolutionary new approaches to this heart-rending problem. The cover shows the happy results. Photograph by Steve Kohler.

SPOT NEWS



Steve Kohler

FIRST Award To Moerlein

Dopamine—a neurotransmitter in the central nervous system—and its cerebral receptors are implicated in Parkinson's disease and schizophrenia. Investigations here at Mallinckrodt Institute of Radiology into the intricate biochemistry of that relationship have resulted in an extraordinary collaboration of scientists.

That cooperation will be central to new work to be done under a \$500,000-plus grant to Stephen M. Moerlein, Ph.D., assistant professor of radiation chemistry in radiology. Moerlein has received a

First Independent Research Support and Transition (FIRST) Award from the Institute of Neurological and Communicative Disorders and Stroke. Moerlein says Mallinckrodt Institute is a unique place to carry out his project because, "A framework for interdepartmental collaboration is already in place."

The money, Moerlein says, will go to expand the Institute's past research on dopamine D-2 receptors to include two new subclasses of receptors in the brain. Most of the previous work has employed positron emission tomography (PET), a quantitative imaging technique available only at advanced research centers. Aside from

Stephen M. Moerlein, Ph.D.

developing new PET radiopharmaceuticals, this work will also evaluate agents for the more commonly found Single Photon Emission Computed Tomography (SPECT). By checking the results of SPECT studies against standards set by PET, widely applicable clinical imaging techniques should result.

The five-year study will focus on the creation of new ligands suitable for imaging dopamine receptor areas; such compounds must retain an affinity for receptors and still carry appropriate nuclides to allow imaging. Moerlein, a chemist and pharmacist, says the work requires cooperation among chemists like himself, neurologists, pharmacologists, and radiologists.

The FIRST Award goes only to researchers in their first five years of scientific endeavor who have not received another major grant. The grant encourages evolution of the investigator's research independence and career development.

MRI Text To Be Penned Here

Contracts have been signed for a new textbook on the subject of magnetic resonance imaging of the cardiovascular system. According to Fernando Gutierrez, M.D., who will

edit, the volume will appear in the summer of 1990 from Yearbook Medical Publishers.

Primarily a Mallinckrodt Institute of Radiology project, the text will include the writings of several staff radiologists, along with the work of an outside physicist. Gutierrez, assistant professor of radiology, plans an all-new text comprehensive in scope.

New Emphasis On Training

Mallinckrodt Institute's annual hyperthermia symposium will be transformed in 1989 into the hyperthermia school for the North American Hyperthermia Group, the national organization of clinicians and scientists working in the field of hyperthermia. The change comes after four highly successful years as an international symposium.

The new format will feature didactic lectures in the morning sessions, with hands-on clinical practice on hyperthermia equipment in the afternoons. Scheduled for June 12-16, 1989, at the Chase-Park Plaza Hotel and Mallinckrodt Institute of Radiology, the school is a presentation of the Radiation Oncology Center here and is sponsored by the American Society of Therapeutic Radiology and Oncology, the American Association of Physicists in Medicine, the Society of Radiation Oncology Administrators, and the Hyperthermia Physics Center.

SPOT NEWS

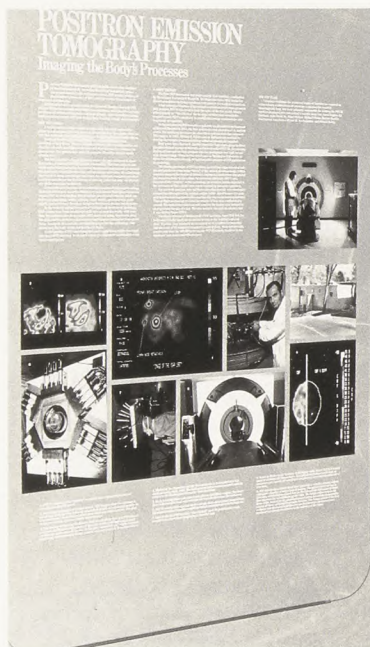
Guest lecturers—recognized experts in hyperthermia from across the country—include William C. Dewey, M.D., director of the Radiation Oncology Research Laboratory at the University of California, San Francisco; Frederic A. Gibbs, M.D., chief of the Section of Radiation Therapy at the University of Utah Medical Center; and Richard A. Steeves, M.D., Ph.D., director of the Division of Radiation Oncology at the University of Wisconsin.

The school is being organized by Bahman Emami, M.D., professor of radiology at Mallinckrodt Institute of Radiology, and Bhudatt R. Paliwal, Ph.D., director of Radiation Therapy Physics, Wisconsin Clinical Cancer Center. Workshops are under the direction of Mallinckrodt's Gilbert H. Nussbaum, Ph.D.

Siegel Named Editor

The reins of the American College of Radiology's Professional Self Evaluation Program have been passed to Mallinckrodt Institute's Barry A. Siegel, M.D., professor of radiology and medicine and director of the Division of Nuclear Medicine. Named editor-in-chief of the series, Siegel is only the second person to hold that position.

The program enables physicians to keep pace with rapid advancements in radiology, to assess their skills, and to maintain their



The historic PET III machine built at Mallinckrodt Institute and used for many years at Brookhaven National Laboratories has been decommissioned and returned to its home. It is now the center of a display on the fourth floor of the Clinical Sciences Research Building. Text and photos tell the story of the development of positron emission tomography (PET), and historic images are displayed.

basic knowledge. At press time, it consisted of 26 free-standing sets of tests and syllabi that measure observational and diagnostic skills. Eleven new volumes are in various stages of development. Each of the subspecialties of radiology is treated, and when the range has been covered the process begins again, resulting in a constant updating of the information.

Siegel takes over as editor-in-chief from Elias G. Theros, M.D., who conceived the program in the late 1960s and now becomes editor emeritus. From the first, the tests

have been "remarkably popular," Siegel says. "The new program on breast diseases sold thirty-three hundred copies in its first two weeks of release." Siegel says that not only practicing radiologists, but residents too have found the tests invaluable as an aid in studying for their board examinations because unknown cases are presented, then carefully analyzed by experts.


The editorship requires eight to 10 hours of work per week, Siegel says, and gives him the responsibility for "the last word on editorial content." The initial appointment is for six years.

Brain Data Goes On-Line

Investigators who explore how the human brain works will get a new yokefellow when a recently funded electronic database of brain research comes on-line sometime before 1991.

Marcus E. Raichle, M.D., who conceptualized the database along with Peter Fox, M.D., Rebecca Kimmel, and Mark Mintun, M.D., says the new computerized library will catalog studies of the brain's function done on positron emission tomography (PET) scanners at Mallinckrodt Institute of Radiology and other top level research centers. The database, funded by a private foundation, will be located at Mallinckrodt Institute.

Raichle, professor of radiology and neurology, says, "Putting together the many experts and all the equipment to do this sort of research is an undertaking not possible for everyone. But this is a national



Steve Kohler

SPOT NEWS

resource, and now it will be available to any researcher with an appropriate question."

Raichle hopes the information amassed in the data bank will prevent the unnecessary repetition of experiments and the attendant exposure of subjects to even the smallest amounts of diagnostic radiation. He adds, "Much of our data could be applied in ways we haven't thought of. And we have a large population of normal scans for a baseline." He hopes the database will promote collaboration between researchers around the world.

Funded by a grant in the amount of almost \$600,000 by the John D. and Catherine T. MacArthur Foundation of Chicago, the database will access files via the desktop workstations familiar to most researchers. Also being considered is a telecommunications network that would allow information to travel over phone lines. Two full-time programmers' salaries will be paid by the grant for three years.

Future refinements may include linking the functional database with a similar project in California, also funded in part by the MacArthur Foundation. In that project, scientists at the Scripps Institute are creating an anatomical database of the brain. By linking Washington University's functional information about how the brain works with the California group's knowledge of brain anatomy, an even more complete picture of the human brain's operation will be available to investigators.

Doing Good, Doing Well

In limited partnership with a California-based venture capital firm, Washington University is marketing products developed in its research laboratories that can do good and—with luck—also do well.

The A/W Company (the "W" is for the University; the "A" stands for Moshe Alafi, the name of the venture capitalist) has several projects under development that blend academia and capitalism. For example, Mallinckrodt Institute researchers have adapted a machine that digitizes spatial information in three dimensions and combined it with a computer program that promises to greatly streamline the operations of hand clinics everywhere.

As yet unnamed, the machine records the range of motion in a patient's wrist, hand, and fingers by

using a stylus and antennae that move within a pulsed magnetic field. The data is immediately computerized, and a report is printed out on the spot. The procedure reduces the time required for a complete hand evaluation by as much as 50 percent.


Physicians no longer need to interpret data recorded in longhand by therapists, and secretaries don't have to transcribe notes. Future versions of the equipment may even be able to identify culprits trying to feign injury by recognizing patterns of fatigue that fall outside normal limits. Because much of the work of hand clinics is done for workmen's compensation or in regard to litigation, those systems may become major beneficiaries of the automation, along with the clinics that gain efficiency.

A/W President Brian Clevinger, Ph.D., says he anticipates sales of perhaps

1,000 first-generation machines at a cost of roughly \$30,000 each. For smaller clinics and offices, the equipment will be available for lease. First-year capitalization for the project has totaled about \$800,000.

Principals in the research have included plastic surgeons Paul M. Weeks, M.D.; R. Evan Crandall, M.D.; and radiologist Michael W. Vannier, M.D. In the image processing laboratory of Vannier, where the technology for the machine was fine-tuned and the software was written, the interest is in the interface between the computer and the hand therapists who will use it. Vannier wants to build better medical systems to help

The hand evaluation station developed in the image processing laboratory greatly increases the efficiency with which the therapist's tasks are performed.



SPOT NEWS

out around the hyper-efficient clinic of the future. As the barriers between the theoretical and the practical come down, he will be able to conduct time and motion studies on the new machine and direct his research more precisely.

PET Applied To Heart Disease

Funded by a one-year grant for \$90,000 from the Edward Mallinckrodt, Jr. Foundation, researchers at Mallinckrodt Institute of Radiology are using positron emission tomography (PET) to establish a basis for the clinical evaluation of patients with advanced coronary artery disease. The study will identify those who would benefit from bypass surgery but are not offered the option because of the surgical risk. Also identified will be patients who would get no benefit from surgery and might not withstand its stress. PET is the only imaging modality that allows *in vivo* noninvasive study of cardiac metabolism.

More than 5.4 million people in the U.S. have coronary artery disease, the nation's leading cause of death and physical disability. Many patients are successfully treated with bypass surgery, but a large number have poor left ventricular function as a result of prior heart attacks or chronically poor blood flow to the heart muscle. They face a seven percent risk of death during surgery compared to only 1.5 percent for those with near normal left ventricular function.

Nearly half of the patients in the high risk category die within three years.


Investigators for the project are Barry A. Siegel, M.D., professor of radiology and medicine and director of Nuclear Medicine at the Institute; Mark A. Mintun, M.D., assistant professor of radiology; and Robert J. Gropler, M.D., instructor in radiology. Gropler, who joined the Mallinckrodt staff in July of 1988, has been awarded the prestigious Clinician-Scientist Award by the American Heart Association to further fund this research project.

On Camera

Mallinckrodt Institute's deep involvement in the diagnosis and treatment of breast cancer goes before television viewers in late April, when a portion of an American Cancer Society special focuses here.

Entitled "Profiles in Survival," the two-hour show makes the statement that "there is life after cancer," according to a spokesperson. The program will be aired in several states, with Jayne Meadows and Steve Allen hosting. St. Louis University and Barnes Hospital will also be featured in the show's vignettes that are being produced for each individual market. Mallinckrodt Institute will be the subject of one of six five-minute St. Louis segments.

A patient whose breast cancer was discovered in its earliest stages on the Mammography Mobile and who subsequently chose breast conservation therapy will be at the center of the piece. Ronald G. Evens, M.D.; Robert J. Kuske, M.D.; and Judy M. Destouet,



Steve Kohler

M.D., from Mallinckrodt Institute, and Barnes surgeon Dorothy Andriole, M.D., will be interviewed on camera.

The special is scheduled to air at 8 p.m. Saturday evening, April 22, on KTVI, Channel 2 in St. Louis.

Jost Chairs Conference

R. Gilbert Jost, M.D., Mallinckrodt Institute's chief of Diagnostic Radiology, co-chaired Medical Imaging III, a conclave of the Society of Photo-Optical Instrumentation Engineers (SPIE) held January 29 through February 3, in Newport Beach, California.

Approximately 700 scientists and engineers from around the globe participated in the four-part conference that treated the newest developments in medical image formation and processing. Jost handled organizational responsibilities and also presented "PACS—Is There Light at the End of the Tunnel?" PACS is an acronym for pic-

Don Bernier, R.T., chief technologist in Nuclear Medicine, recently inscribed a copy of his book's second edition for Ronald G. Evens, M.D., professor and head of the Institute. Nuclear Medicine Technology and Techniques has been revised for 1989. Bernier is one of four editors of the text that is used in 140 teaching institutions. More than 5,000 copies of the first edition were sold.

ture archiving and communication system, an electronic method of cataloging and transmitting radiological images.

Others affiliated with Washington University participating in the meeting and presenting included G. James Blaine, D.Sc., associate professor of computer science in radiology; Stephen M. Moore, M.S., research engineer; Rexford L. Hill, M.S., associate professor of computer science in radiology; John B. Zimmerman, Ph.D., assistant professor of computer applications in radiology; and Jerome R. Cox, Sc.D., chairman and professor of the Department of Computer Science.



A black and white photograph of a forest floor covered in fallen leaves, with several tall, thin trees in the background. The scene is captured from a low angle, looking across the leaf-covered ground towards a line of trees. The lighting is soft, creating a serene and somewhat somber atmosphere. The text 'Overcoming Infertility' is overlaid in a white, elegant script font in the lower right quadrant of the image.

*Overcoming
Infertility*



Steve Kohler

Overcoming Infertility

By Vicki Kunkler

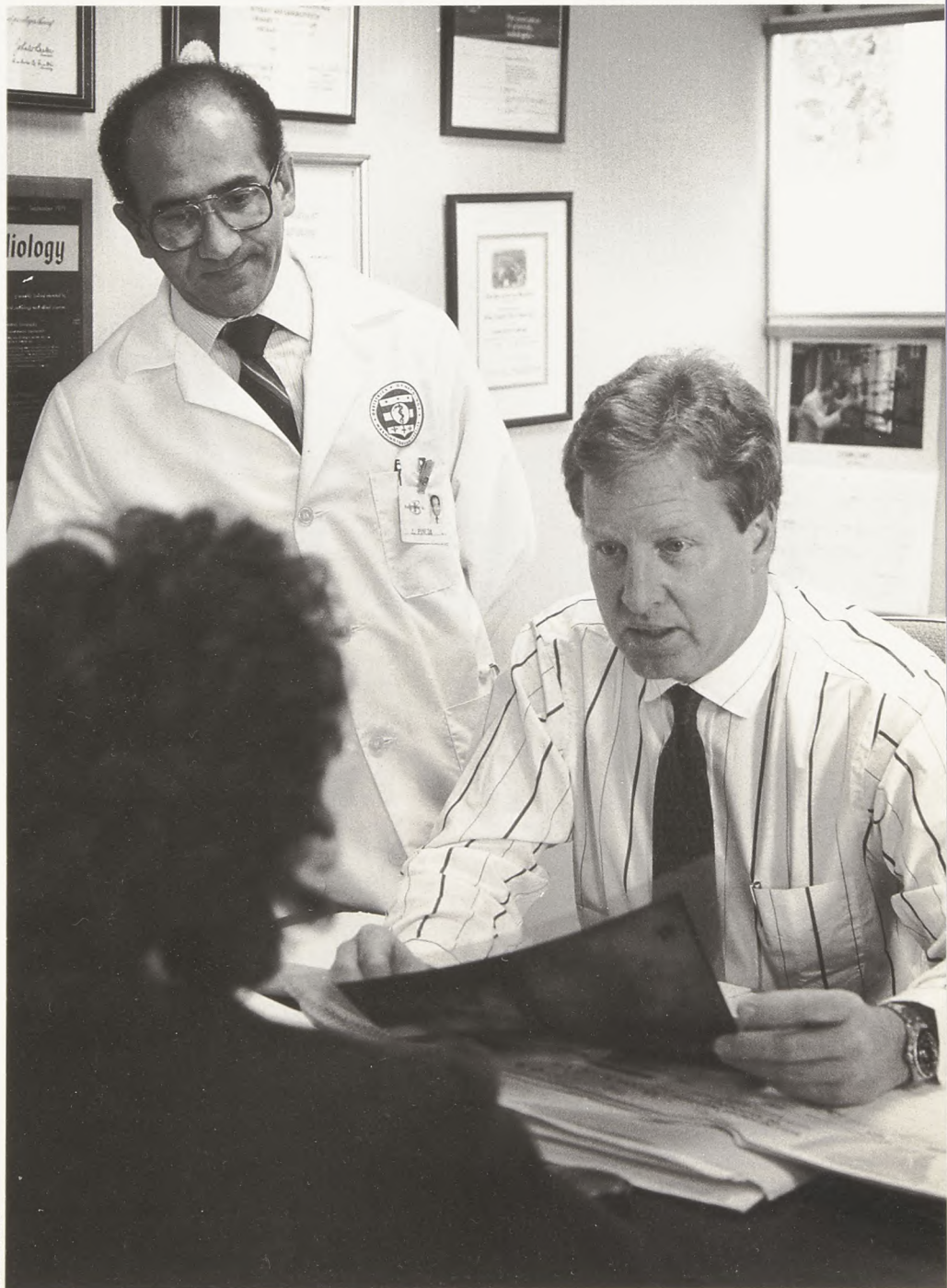
Six years ago Sheila Wilson never thought about infertility. After she and husband Bill decided to start their family, Sheila became pregnant within a few months. Their son Danny was the result of that uncomplicated pregnancy and easy delivery. But by November of 1988, Sheila found herself in the last throes of a two-year attempt to overcome her inability to conceive a second time. After months of consultation and testing, she made her first appointment with Jorge Pineda, M.D., assistant professor in the OB-GYN Department in Washington University School of Medicine's Division of Reproductive Endocrinology. Pineda and Bruce McClennan, M.D., professor of radiology, are collaborators in an innovative procedure that offers new hope for many of the 15 percent of couples in the United States who are affected by infertility.

“I gained only 10 pounds during my pregnancy and didn’t experience any of the side effects commonly associated with pregnancy. Because I had such an easy time, the decision to have more children seemed very natural,” Sheila said.

The Wilsons had decided to wait until Danny was three years old before completing their family circle with another child. When Sheila didn’t conceive as quickly this time, she wasn’t concerned. Her days were spent caring for an active youngster and managing a home. She was happy and, for the moment, fulfilled. But as time passed, each month would begin with anticipation and end with anguish when it became evident there would be no baby this month. After 13 months had passed with no pregnancy, the longing for another baby became a most important issue. Four-year-old Danny was no longer in the cuddly baby stage; he was an independent young boy who was more interested in being like Daddy than in being Mommy’s little boy.

Infertility—the inability to conceive after one year of unprotected intercourse—became a reality for the Wilsons. Sheila and Bill had become one of the 3.5 million infertile couples in the United States. Their lives began to include Sheila’s gynecologist, Bill’s urologist, hundreds (or so it seemed) of tests, even artificial insemination, and always that feeling of loneliness and emptiness. The ultrasound performed after the artificial insemination showed “something wrong,” Sheila said, and that’s when her gynecologist suggested an infertility specialist.

The specialist suspected an obstruction in the Fallopian



Steve Kohler

Jorge Pineda, M.D., assistant professor in Washington University Medical School’s Division of Reproductive Endocrinology, and Bruce L. McClennan, M.D., professor of radiology, confer with a patient about her chances for achieving pregnancy following selective ostial salpingography and recanalization.

Overcoming Infertility

tubes and scheduled Sheila for a hysterosalpingogram (HSG), the traditional test for tubal blockage that involves injection of a contrast agent into the uterus. The accompanying X rays confirmed the initial suspicion, but an additional procedure, a diagnostic laparoscopy, was needed to determine the extent of the blockage. The culprit was assumed to be an infection that had gone undetected and caused not only the blockage in both

With selective salpingography and recanalization, no surgery is involved.

tubes but also scarring around the ovaries. In 50 percent of the cases, infertility is attributed to the female, with the major cause being pelvic inflammatory disease (an infection). An obstruction in the tube hinders conception by preventing egg contact with the sperm.

Sheila and Bill had some tough decisions to make. Sheila could have corrective surgery that meant four to five hours in the operating room with no guarantee that enough of her diseased tubes could be saved to produce a pregnancy. Or they could choose *in vitro* fertilization (IVF) which offers a success rate of only 16 percent and car-

ries a price tag of about \$5,000 for each attempt. And, the other choice—they could decide to keep their family circle at three. “The idea of four to five hours of surgery was frightening and *in vitro* was out because of the cost. But we weren’t ready to give up,” Sheila said.

Her determination and desire to have another child brought Sheila to Washington University School of Medicine and Mallinckrodt Institute of Radiology. “I wanted a second opinion. I wanted to know that surgery was all that was left for me. I asked my doctor to refer me to someone who specialized in my problem. He sent me to Doctor Pineda.”

Pineda offered the Wilsons yet another choice. A new procedure, perfected by Amy Thurmond, M.D., of the Oregon Health Sciences University in Portland, was producing a good success rate in identifying and subsequently correcting tubal blockage. The two-step technique, called selective ostial salpingography and recanalization, involves assessing tubal patency by first delivering a contrast agent via a catheter directly into the Fallopian tube. After an X ray determines the extent of the blockage, if any, and if the blockage is located in the cornual area (that portion of the tube just outside the uterus), an attempt can be made to clear the obstruction. Selective ostial salpingography—the X-ray portion—more clearly defines tubal anatomy

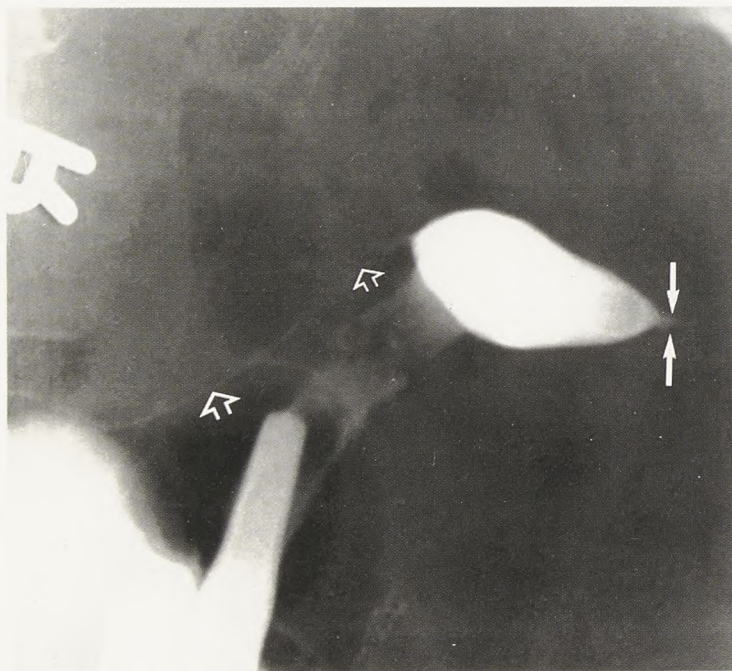
than does conventional HSG, which placed the contrast agent only into the uterus, and eliminates the waiting period women must endure with other treatments.

Pineda stresses that the effectiveness of recanalization is related to the specific location of the obstruction. Under fluoroscopic guidance, a soft-tipped flexible guidewire is fed inside a catheter through the cervix, across the uterus, and into the tube. The guidewire is advanced until the obstruction is cleared.

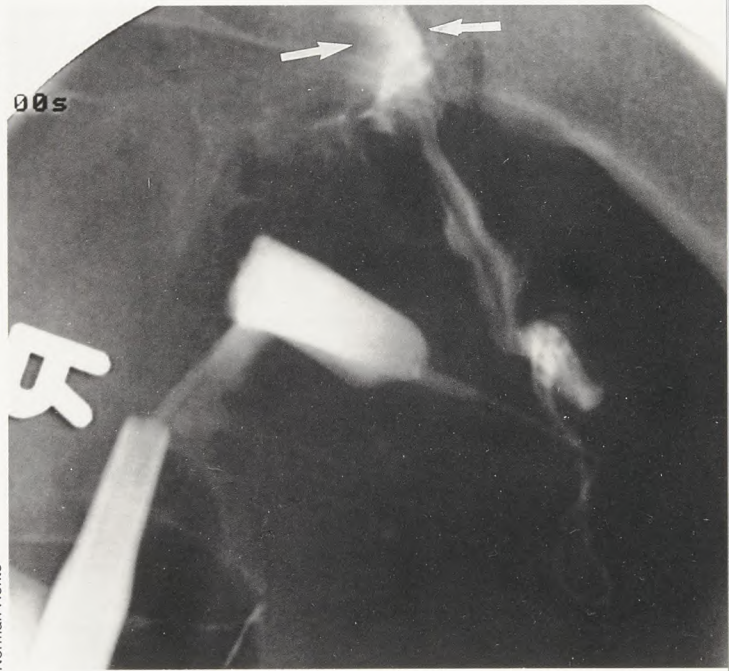
According to Pineda, he and Randall R. Odem, M.D., and Michael J. Gast, M.D., Ph.D., of Washington University OB-GYN Consultants, in collaboration with Mallinckrodt Institute, have used this procedure for more than 20 patients referred to them over the past year. “We are one of the first major medical centers in Missouri and in the Midwest to offer this procedure.

“If the numbers hold true, there is a thirty percent or better chance of achieving pregnancy.”

We act as a referral center for patients who have been evaluated and then sent to us for specialized care. More doctors and patients need to know there is a diagnostic alternative to surgery.”



Norman Hente



Norman Hente

The hysterosalpingogram on the left shows a total occlusion of the left Fallopian tube (solid arrows). Partial filling of the right Fallopian tube, which is known to be diseased, can also be seen (open arrows). After a selective injection of a small catheter over the guidewire that extends well out into the left tube, the image on the right shows a filled tube with spill into the peritoneal cavity (arrows). This demonstrates that the tube is now open.

greatest drawing cards is the price tag: \$600 to \$800, or about one-third the cost of diagnostic surgery. Since there is no surgery involved, there is less risk to the patient. And another real plus for so many women who have had to face months of not knowing whether a new technique has been successful is the immediate result of selective salpingography. If the X ray shows the tube is blocked, clearing the obstruction, or recanalization, can be attempted at the same time.

For couples who have exhausted their physical, emotional, and financial resources in their longing for a baby, the advantages of low cost and immediate answers are secondary to the new hope of achieving pregnancy offered by this

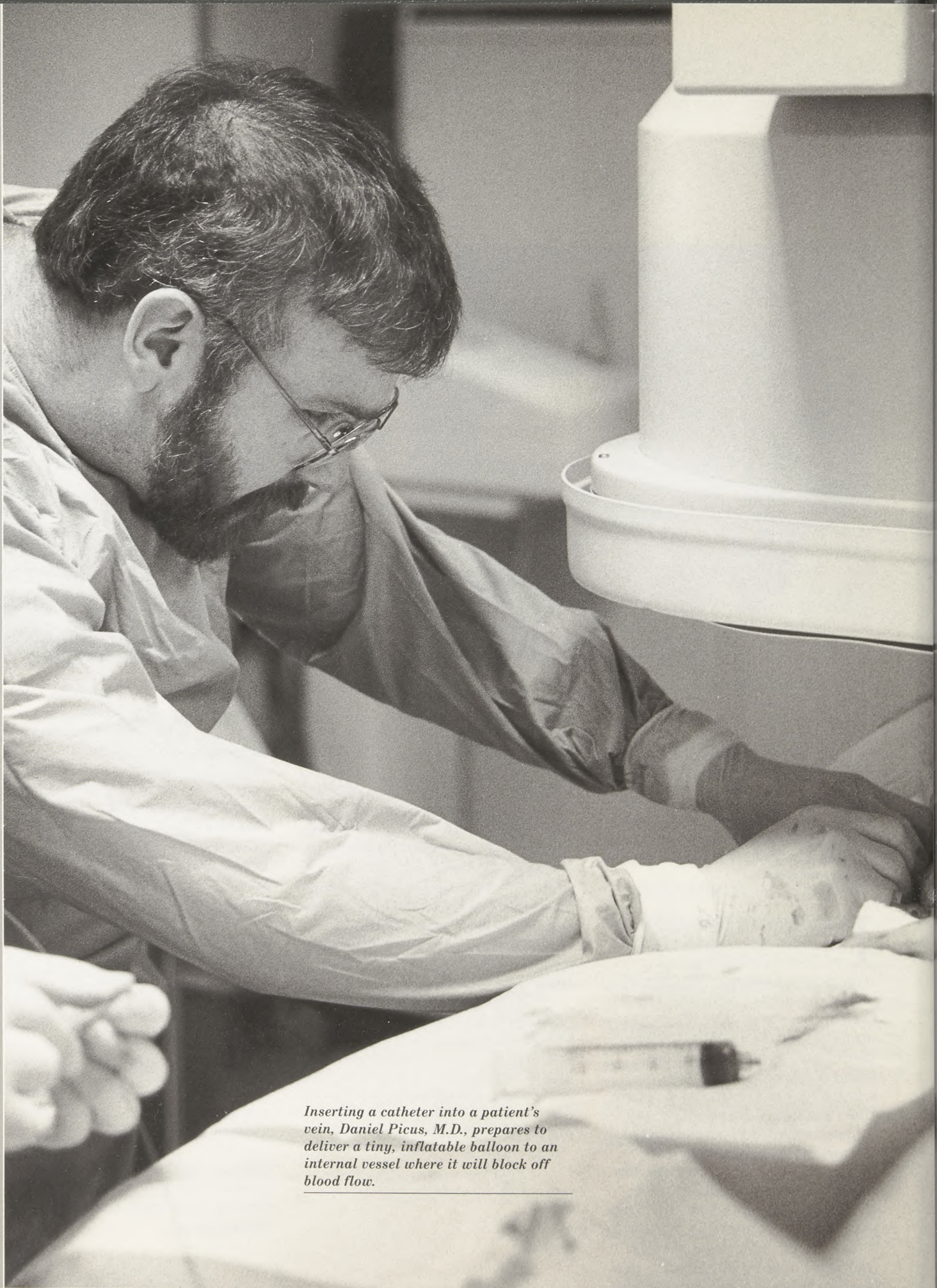
procedure. "If the numbers from Doctor Thurmond's cases and ours hold true, there is a thirty percent or better chance of achieving pregnancy with this procedure. If there are no additional problems other than blocked tubes, conception could occur right away, although I recommend waiting one menstrual cycle before attempting to conceive," said Dr. Pineda.

The procedure went well for Sheila Wilson. According to McClennan, "Her right tube was very diseased but was able to be partially opened. The left tube is completely clear now. This was one of our best technical triumphs."

As for the Wilsons, it's a wait-and-see period, but chances are good their family circle will soon be complete. □

Editor's note: The names of the patient and the members of her family have been changed at their request.

In her presentation at the fall meeting of the Radiological Society of North America in Chicago, Thurmond pointed out that although the technique is new, the diagnostic application has already proven useful and should not be considered experimental. The advantages over current alternatives are many. In selective salpingography and recanalization, no surgery is involved, unless other problems are detected during the procedure, and can be performed on an outpatient basis in less than 45 minutes. Minimal, if any, medication is required, and then usually in the form of a short-acting relaxant. One of the



Inserting a catheter into a patient's vein, Daniel Picus, M.D., prepares to deliver a tiny, inflatable balloon to an internal vessel where it will block off blood flow.

Family

MATTERS

Radiology Intervenes in the Most Common Cause of Male Infertility

By Steve Kohler

In a sense, Jim and Libby Doell are alone. They live together as husband and wife without the children they so achingly want. For the five years of their marriage, they've been trying unsuccessfully to start a family and fending off an increasing feeling of emptiness. Now, at 29 and 33 years of age, they've begun to experience the added pressure of time.

In another sense, however, the Doells are not alone; one in six U.S. couples of childbearing age is involuntarily childless. In nearly 40 percent of the cases, the difficulty in conceiving can be attributed to the male. That his plight is shared by more than a million and a half other men is little comfort to Jim Doell. No matter how rational he tries to be, no matter how supportive Libby is, Jim still feels lonely and threatened, his masculinity somehow at issue.

Family

MATTERS

What is a real comfort to the Doells (whose names have been changed here because of the sensitivity of the subject) is the fresh hope that has been provided through interventional radiology treatment. With this procedure, infertility is being reversed when a condition known as a varicocele is embolized, or blocked off, without the need for surgery. Success rates approach 50 percent — each victory measured when a baby is conceived.

A varicocele like Jim's forms when missing or inoperative valves in the large internal spermatic vein that leads from the scrotum back to the heart allow the blood to stand in a column. Under constant pressure, the vein distends, much like varicose veins in the legs of a person always on his feet. The tangle of small vessels surrounding the testicles becomes engorged, forming a varicocele.

According to Daniel Picus, M.D., assistant professor of radiology and chief of the interventional section at Mallinckrodt Institute of Radiology, varicoceles occur on the left side about 95 percent of the time, perhaps because the physiology places a column of blood in a more direct line on that side. Often painful, varicoceles are also the most common cause of male infertility. No one knows why.

The most widely held theory—that the increased blood volume in the enlarged veins elevates the temperature of the testicles beyond the level at which the production of sperm properly occurs—remains unproved. According to Todd Garvin, M.D., instructor in urologic surgery at

Washington University School of Medicine, the thinking is that the testicles' location outside the main body cavity is a device for keeping them cooler than body temperature. Increased blood flow may interfere with the necessary temperature differential. Other suggestions include the idea that hormones refluxing down the enlarged vein may impede spermatogenesis. But that is even less certain. Although no animal other than man is known to suffer naturally from varicoceles, researchers have created artificial varicoceles in rats and dogs. Still, research into the subject has been slow in coming in the absence of com-

Success rates approach 50 percent—each victory measured when a baby is conceived.

parable animal models, Garvin says. However, physicians continue to successfully treat varicoceles as a cause of infertility.

What is known is that about 10 percent of the general male population is affected, but in nearly 40 percent of infertile couples the man suffers from a varicocele. For whatever reason, the condition often results in

lower than normal sperm counts and abnormalities in sperm motility and shape. It's a syndrome known as "stress pattern," Garvin says, that is marked by immature sperm. It has been associated with varicoceles since 1929.

For years, varicocele patients have been offered vascular surgery to correct the problem. Urologic surgeons like Garvin tie off the spermatic vein and relieve the pressure. The distended veins then shrink to their normal sizes. The return of blood to the heart formerly carried by the large spermatic vein is managed by a network of smaller veins over less direct routes. In about 10 percent of the cases—some say as many as 25 percent—those smaller, collateral veins themselves distend, and the varicocele recurs. Identifying all the collaterals in the surgical suite is often impossible, Garvin says.

Such an operation may be done under local or general anesthesia, often without hospitalization. However, the incision requires two weeks or more of painful recovery time. Exact costs are difficult to calculate because each case differs, but the price tag hovers above the \$2,000 mark.

What Picus and his colleagues—M. Victoria Marx, M.D., and Marshall E. Hicks, M.D.—in the burgeoning field of interventional radiology offer is a percutaneous embolization procedure that can be accomplished on an outpatient basis. Jim Doell came to Mallinckrodt Institute on a Friday morning in December of



Steve Kohler

Daniel Picus, M.D., assistant professor of radiology and chief of Mallinckrodt Institute's interventional section.

1987 and was at home to watch "Miami Vice" on television that evening. He returned to his work as a computer scientist the following Monday after a weekend of relaxing. And his total outlay—had insurance not covered it—would have been more like \$1,200.

In the procedure to embolize the spermatic vein, the vessel is literally blocked off so that no blood can flow. But the work is done from inside the vein. A catheter introduced via either the jugular vein (in the neck) or the femoral vein (in the groin) is guided to a site in the spermatic vein where it will be blocked off, along with all or most of the collateral veins. "We used to approach through the jugular, because the route is more direct," says Picus, "but patients prefer not to be approached from the neck. Now we enter through the femoral vein almost exclusively." The puncture of the vein is the only incision necessary, and no stitches are needed to close the small wound.

Attached to the end of the catheter, which is just a long tube, is a small, inflatable balloon. The balloon is guided by radiography to the predetermined site at which the vein will be occluded. Then the balloon is filled with enough opaque contrast medium so that its position can be checked on film. As it inflates, it locks itself in place. A small risk is that the vein may be in spasm and will later relax and enlarge, freeing the balloon. But venograms before and after the procedure mitigate that difficulty.

Family

MATTERS

A one-millimeter balloon inflates to four millimeters in diameter, and a larger size inflates to eight millimeters.

A tug on the catheter releases the balloon, which immediately seals itself and forms an obstruction to all blood flow. Clotting and the growth of fibrous tissue encapsulate the balloon, making the blockage permanent.

Jim Doell says he felt no pain and may only have imagined the odd sensation he recalls in his torso as the catheter was guided into his spermatic vein. He watched the proceedings on a

“Embolization will definitely do what surgery will do.”

monitor to see the progress of the catheter in his venous system. Particularly fascinated because his work involves computer graphics, Jim gives the video display high marks as an aid to his understanding. He received only a mild tranquilizer and a local anesthetic and was relaxed enough to doze off during the procedure, he says.

Picus says he sometimes uses small metal coils in place of the balloons. “They are less expensive, and a good option when collateral veins must be blocked off individually. They can be more difficult to place. They work because small fibers on their surfaces cause the vein to sclerose. That takes time, so you can’t check on their progress immediately,” he explains. Other researchers, working to refine the procedure, are experimenting with boiling contrast medium and other agents to cause the vein to sclerose.

The concept for occluding the spermatic vein via percutaneous catheterization originated in Europe, where the procedure is now the most common method of managing varicoceles. Injectable glues were the first agents tried, according to Robert I. White, M.D., professor and chairman of radiology at Yale University, who has long experience with the embolization procedure. The earliest work began about 12 years ago and spread to this country during the past decade.

White’s own investigations include a study of 300 patients treated for varicoceles, then followed for 18 months. His results show 41 percent of the men successfully impregnated their wives following therapy. In cases where the woman also showed a fertility-related abnormality, the number dropped to 31 percent. White and Picus agree that the procedure is a sound one, with much to offer patients. “It will definitely do what surgery will do,” White says.

But it’s still uncommon. Urologist Garvin says he presents the options of surgery and embolization to all of his varicocele patients, and two-thirds choose surgery despite the advantages of the newer procedure. Garvin is not sure why. “Maybe it’s that embolization is still seen as experimental, and many patients

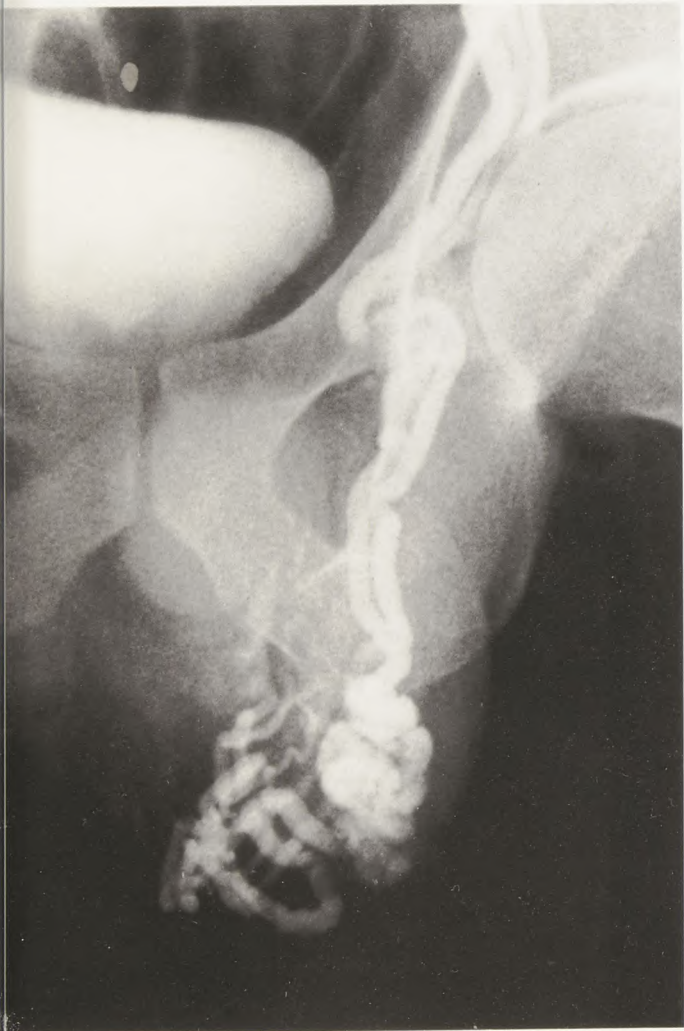feel more comfortable with the traditional surgical approach,” he says. His experience with those patients who do select the radiological technique has been “very positive.”

For patients who have undergone surgery only to have their varicoceles recur, embolization by an interventional radiologist represents the only avenue still available. The technique has proved itself in such cases as well, producing results comparable to those among new patients.

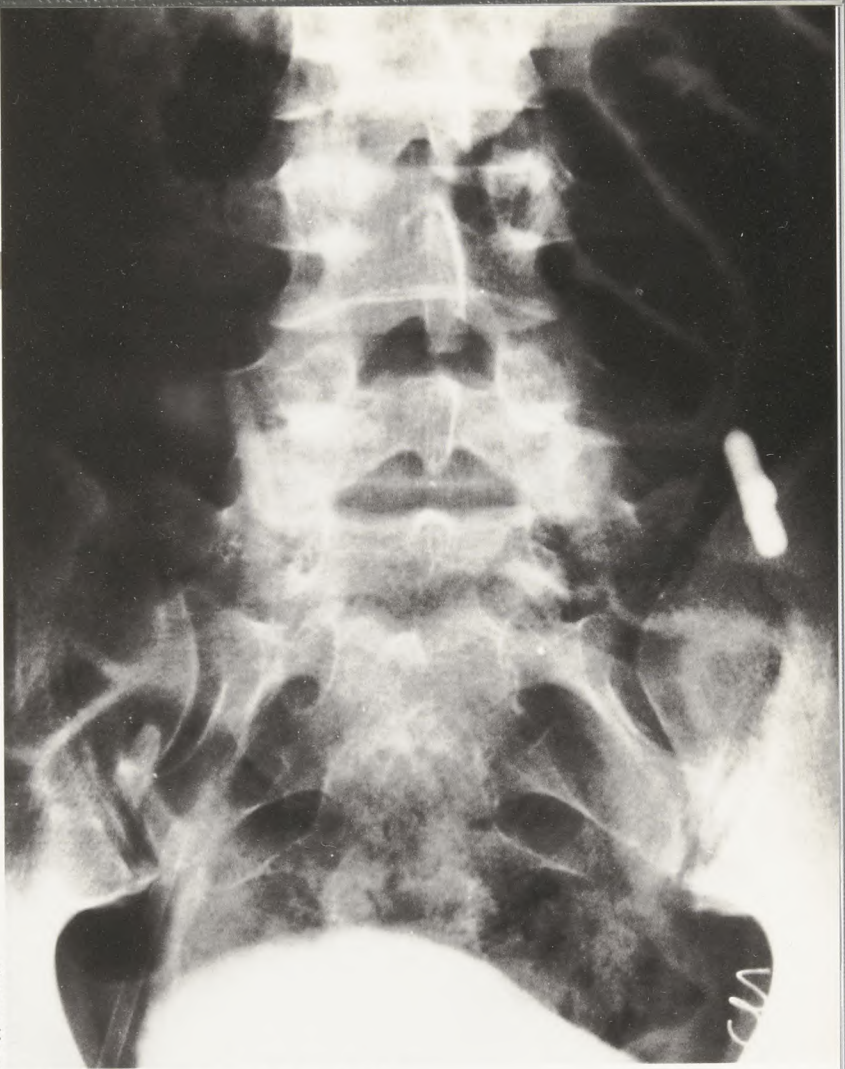Picus and Garvin both think the small number of men choosing embolization therapy is partly attributable to a limited awareness that the procedure is available. They predict that more and more patients will choose the less costly outpatient procedure that results in a lower rate of recurrence.

The post-embolization future for Jim and Libby Doell is hopeful, but without guarantees. As Garvin says, “Infertility is a very complex issue; there’s not one button to push to make everything work again.”

It’s been more than a year since Jim’s varicocele was repaired at Mallinckrodt Institute. The first four months probably should not be counted, since a return to normal sperm production may take that long. A semen analysis at six months showed the number, motility, and shape of Jim’s sperm all back into the low-normal range,



Thomas Murry



Thomas Murry

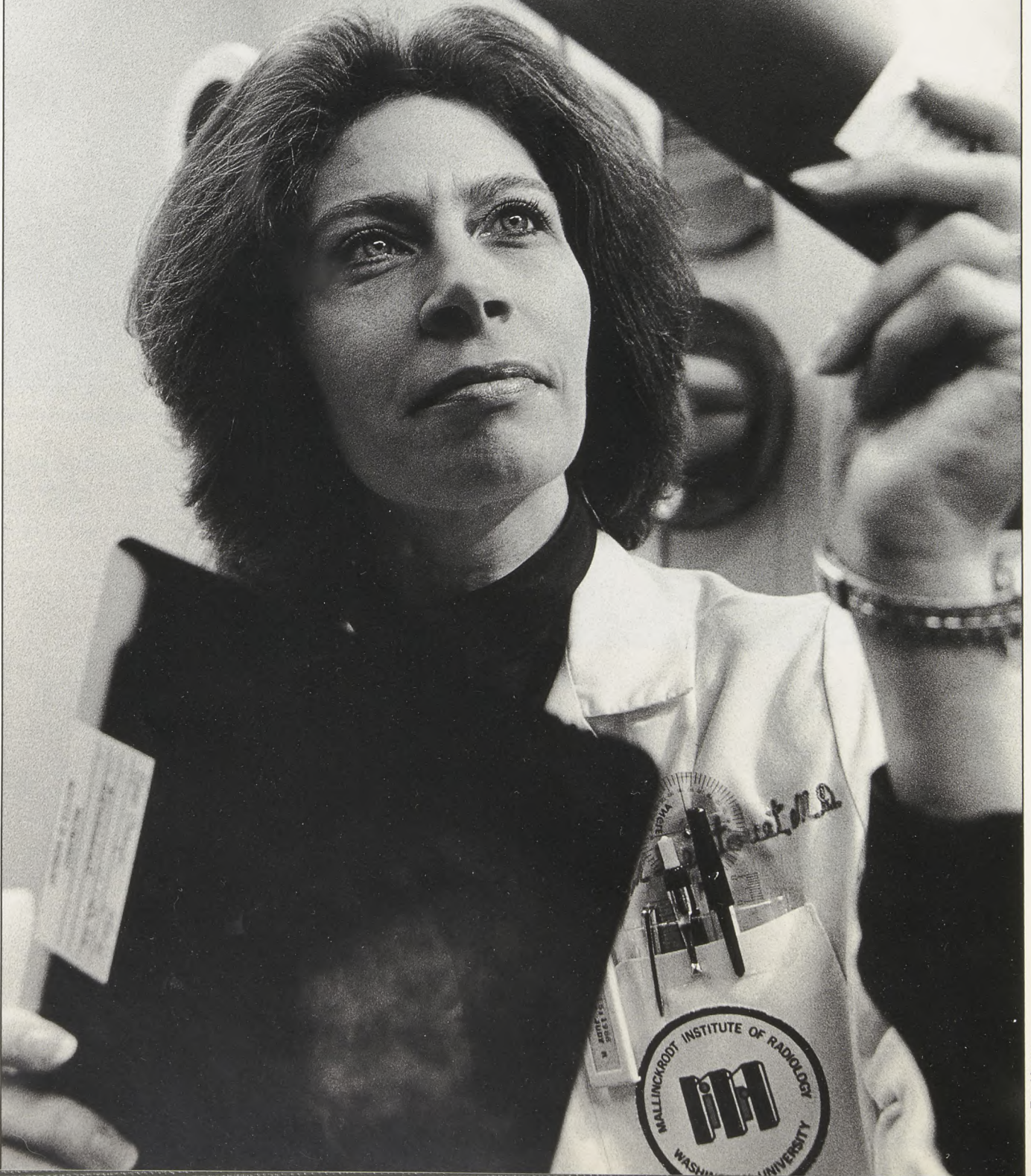In a classic before and after study, the effects of embolization are apparent. The left image reveals the distended veins that cluster around the testicle of a varicocele patient. In the right image, the balloon that blocks the spermatic vein can be seen near the right middle, and a metal coil of the type sometimes used to sclerose collateral veins is visible at the lower right. With the spermatic vein blocked, the varicocele shrinks and fertility is often improved.

and the couple began to hope again for a happy resolution to their trouble.

But while they wait to see if their case falls into the lucky 50 percent that achieve pregnancies, only one number continues to matter to the Doells. Their

route to parenthood has been tortuous, full of emotional upheaval and private doubts. They hope that radiology has helped, but they're determined to succeed one way or another. □

Judy M. Destouet, M.D., associate professor of radiology and head of Mallinckrodt Institute's mammography program, believes that a better breast implant is possible.



MINIMIZING THE RISK

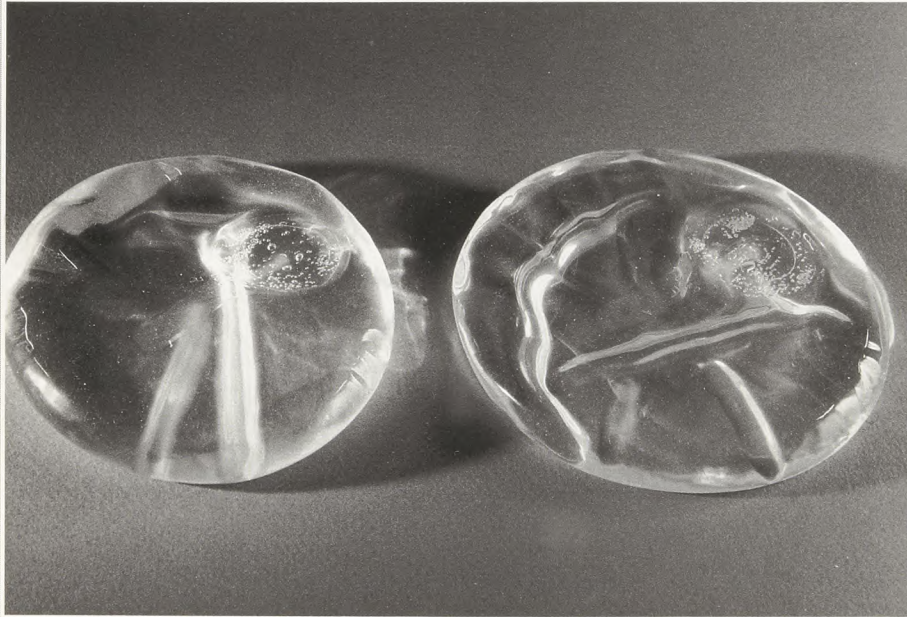
A Call for a Radiolucent Breast Implant

By Steve Kohler

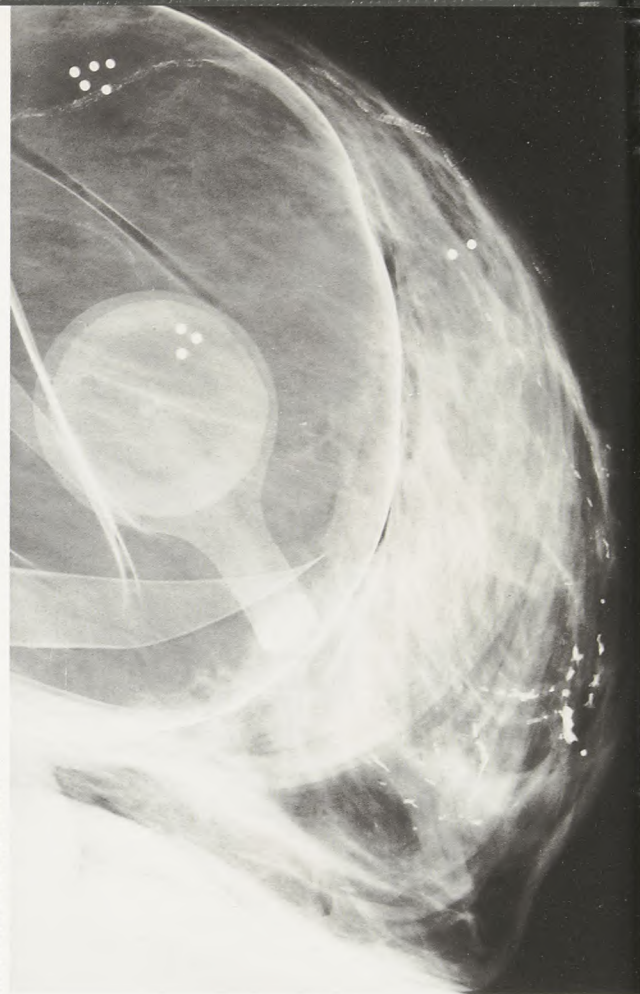In 1986, 590,550 Americans underwent cosmetic surgery, up 24 percent from two years earlier. Seeking improvement, they enlarged, rearranged, scraped off, and vacuumed away tissue, hopeful that they had accurately balanced the risks of cosmetic surgery with the benefits of an altered appearance. In among the total were roughly 150,000 women who had their breasts enlarged in a procedure known as augmentation mammoplasty—the surgical placement of a saline- or silicone-filled implant behind the glandular tissue or beneath the muscle of the chest.

Each week, as many as 10 women with augmented breasts visit one of Mallinckrodt Institute of Radiology's facilities for a mammogram—medicine's best technique for detecting breast cancer when it is still small and curable. But because silicone blocks X rays, mammograms for such patients are not as effective as they should be, according to Judy M. Destouet, M.D., who oversees Mallinckrodt's mammography program.

MINIMIZING THE RISK



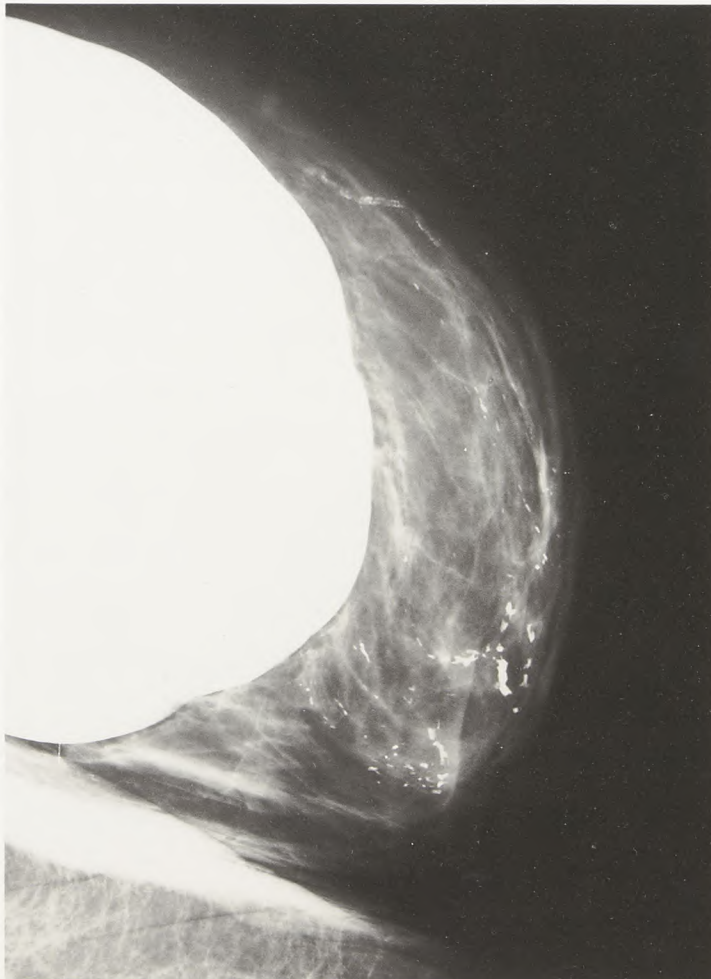
Steve Kohler & Norman Hente



Breast cancer affects one woman in 10, those with implants and those without alike. But in women with augmentation, a recent study shows that breast cancer may go longer before detection, progressing to a more advanced stage because the early signs were not apparent in mammographic examinations.

About 2 million women have had their breasts enlarged since the early 1960s when the procedure became widely available. And radiologists have been aware of the special needs of women with augmented breasts. Destouet says, "We've lived with it, doing the best job we could."

Implants influence mammography in several ways. The implant, opaque to X rays, blocks between 22 and 83 percent of the glandular tissue. Microcalcifications and small masses—the nonpalpable lesions often found only by mammography—are harder to image in the augmented breast because the glan-



Steve Kohler & Norman Hente

Clockwise from top left: To the unaided eye, breast implants filled with peanut oil (left) and silicone (right) look much the same. The other images show how different they are mammographically. The peanut oil implant does not hide the simulated calcifications, while the conventional silicone implant is radiopaque, obscuring the physician's view of critical information. Though peanut oil is not a real possibility as an implant filler, a material of similar atomic number and physical density is a goal of Destouet's research.

dular tissue is compressed by the implant to a uniform density. Scar tissue that forms around the implant, silicone that leaks from the shell, and calcifications that sometimes form on the surface of the implant, perhaps as the body's response to a foreign object, also contribute to the problem. That these same changes may make breast self-examination more difficult even as it becomes more important is doubly worrisome.

Radiologists have coped with these difficulties since the mid-1970s when they were first recognized. To overcome these obstacles to accurately visualizing breast tissue in women with implants, a "pinch" or displacement view is often used. In this technique, the tissue is pulled away from the prosthesis and selectively compressed. But Destouet says such a procedure is sometimes difficult to do correctly and can be impossible when the implant is surrounded by a firm capsule, as occasionally happens.

The real significance of the difficulties in imaging augmented breasts did not become clear until June of 1988, however, when Melvin J. Silverstein, M.D., and his colleagues at The Breast Center in Van Nuys, California, published a revealing paper. The researchers studied 20 patients with previously augmented breasts who had been treated for breast cancer. They reported that all 20 women were first diagnosed with palpable masses; mammography had failed to find any of their cancers. Additionally, 13 of the women, or 65 percent, already had a spread of the cancer to their axillary lymph nodes—a sign of advanced disease. That compares to the nonaugmented population in which only 28 percent of the women with breast cancer had lymph-node involvement at diagnosis. Clearly, mammography was not serving women with augmented breasts.

Women with breast implants should have a displacement or "pinch" view mammogram.

"That data really shook us up," Destouet says.

Silverstein and others have since issued recommendations for imaging the augmented breast, and Destouet agrees with them. Silverstein says, "We suggest a displacement view, and

we discourage augmentation in high-risk women. Whenever possible, we suggest an implant behind the muscle." Destouet adds that women 35 years of age and older who are considering augmentation should have a pre-operative mammogram and then annual mammography, along with physical examination by a physician experienced in the treatment of augmented breasts. She reiterates that any woman with a strong family history of breast cancer "should think very hard before having augmentation."

But Destouet is guided by a philosophy that has prompted her to go further. Reasoning that it is the implant's physical density that causes it to obscure the radiologist's view, she and her colleagues determined to explore the possibility of a radiolucent implant material. Is it possible, they wondered, to develop a better implant that feels like the human breast, that is compatible with living tissue, yet doesn't obscure breast tissue on a mammogram.

A first approach to a medical manufacturer began promisingly, with the company providing several experimental implants for testing. The prototype fillers were used only to determine an appropriate atomic number and density for a material, not suggested as real-world possibilities. Peanut oil, sunflower oil, and gelatin were tested, along with saline, conventional silicone, silicone in a special low-bleed shell,

MINIMIZING THE RISK

and the empty low-bleed shell alone. Each of the implants was X-rayed overlying a mammography phantom that simulated the microcalcifications and soft-tissue masses of breast cancer.

Results were unequivocal. The shell alone did not significantly affect resolution, but the gelatin allowed only limited visualization of the microcalcifications and obscured soft-tissue masses. Silicone gel, saline, and the low-bleed shell with gel completely obscured the radiologist's view of all the artifacts.

However, the peanut oil and sunflower oil implants had little effect on resolution, clearly suggesting that an implant material with a physical density similar to breast tissue is possible, if suppliers will only manufacture and test it. The implant Destouet hopes to see as an eventual result of the study won't be filled with a vegetable oil, but it will be of a substance similar to the oil in density and atomic number.

“Of course, extensive biocompatibility tests will have to be done,” she says, “beginning with animal studies for rejection. We also need to create a new shell and valve material.” And an interested supplier will have to be found; negotiations with the original company fizzled for reasons that executives declined to explain. A new firm has now joined the research, and Destouet hopes for renewed vigor on the project. Silverstein predicts that the process will be

*In the long run,
a better implant
should be developed.*

a difficult one because mammography is a subtle technique that can be disrupted by small complications.

Though some of her colleagues have been critical of Destouet, concerned that the issue raises unnecessary anxieties among patients, she nonetheless has been asked by the American Society of Plastic and Reconstructive Surgeons to participate in establishing official guidelines for mammography in the augmented patient.

And she continues her commitment to a three-pronged assault on the issue. She works on the professional level by authoring and presenting papers. The *Journal of Plastic and Reconstructive Surgery* will soon publish “The Effect of Breast Implants on the Radiographic Detection of Microcalcification and Soft Tissue Masses”—and other papers have been submitted for review. On another level, suppliers of medical equipment continue to be pressed to contribute to the research by developing radiolucent materials and performing biocompatibility tests.

But perhaps most importantly, women are being reached via Destouet's public speaking engagements, her appearances on local and network television, and stories about her work in such publications as *USA Today*, *Good Housekeeping*, and others. Her goal, she says, is to “alert women to potential problems with the dense implant.” Thereby, she hopes to reduce the risks involved in their decisions to seek altered appearances. □

FYI

THE DIRECTOR'S OFFICE REPORT

NEW STAFF

David E. Beecher, M.S., research associate in radiology, Division of Radiation Sciences

Eric E. Klein, M.S., instructor in radiation physics in radiology, Division of Radiation Sciences

John W. Matthews, D.Sc., research associate in radiation physics in radiology, Division of Radiation Sciences

Marianne Mildenerger, M.D., assistant in radiology, Division of Radiation Oncology

OFF STAFF

Dennis A. Moore, Ph.D., research associate in radiology, Division of Radiation Sciences

Kenzo Ohtsuka, Ph.D., research associate in cancer biology in radiology, Division of Radiation Oncology

Arthur A. Porporis, M.D., assistant professor in clinical radiology, Division of Diagnostic Radiology, has retired from practice.

VISITING PROFESSORS & INVITED LECTURERS

Bahman Emami, M.D., professor of radiology, as invited lecturer, spoke on "Hyperthermia and Chemotherapy" at the 5th Biennial Conference of the Indian Association of Cancer Chemotherapists, Bombay, India, February 17-19.

Harvey S. Glazer, M.D., associate professor of radiology, spoke on "CT of Pulmonary Collapse," "CT of the Mediastinum," "CT of 'Cystic' Neck Masses," and "CT of Mediastinal Vessels with MRI Correlation" at the Winter Imaging Seminar sponsored by the University of Pennsylvania Hospital, Cancun, Mexico, February 20-24. Glazer presented "CT of Pulmonary Collapse," "Differential Diagnosis of Mediastinal Pathology," "CT of Neck and Larynx," and "Pitfalls

in Chest CT" at the International London Course in Whole Body Computed Tomography, Gleneagles, Scotland, March 19-23.

Louis A. Gilula, M.D., professor of radiology, presented the refresher course "Imaging of the Wrist" at the American Academy of Orthopedic Surgeons, Las Vegas, February 12. He spoke on "Tenography of Foot and Ankle," "Analysis of the Approach to Carpal and Ligamentous Instabilities of the Wrist," and "CT and 3-D CT of Foot and Ankle" at the Skeletal Radiology meeting, Phoenix, March 11-14. Gilula presented "Practical Uses of 3-D CT of the Wrist," "Arthrography of the Wrist," and "Wrist MRI" at the Sympo-

sium on the Wrist at the Institute Francois de la Main, Paris, France, April 6-8. He also organized the International Wrist Investigators' Workshop, Paris, France, April 5.

Jay P. Heiken, M.D., associate professor of radiology, presented "MRI of the Liver and Upper Abdomen," "MRI of the Retroperitoneum," and "MRI of the Pelvis" at Seminars in MRI, sponsored by the Medical College of Wisconsin, Snowbird, Utah, February 25-March 4. Heiken lectured on "The Detection of Liver Metastases: Technique and Accuracy" and "CT Evaluation of Colonic Disease" and presented workshops on "CT of the Gastrointestinal Tract" and "CT Evaluation of Retroperitoneal Lymph Nodes and Masses" at the International London Course in Whole Body Computed Tomography, Auchterarder Perthshire, Scotland, March 19-23. He also presented "CT of the Retroperitoneum," "CT of the Pancreas," "CT Evaluation of Renal Masses," and "CT Evaluation of Pelvic Neoplasms" in a course sponsored by the University of British Columbia, Vancouver, February 5-10. As visiting professor, Heiken presented "CT of the Retroperitoneum" and "CT of the Peritoneum" at the University of Munster School of Medicine, Munster, West Germany, March 16-18.

Bruce L. McClellan, M.D., professor of radiology, presented "Extracorporeal Shockwave Lithotripsy" as guest speaker at the Chicago Radiological Society meeting, January 19. As visiting professor, McClellan presented "CT of Indeterminate Renal Masses" at Rush Presbyterian St. Luke's Medical Center, Chicago, January 19. He spoke on "The New Contrast Media: Update 1989" as the Marshall Eskridge Lecturer of the Southern Radiological Conference, Point Clear, Alabama, January 27-29. McClellan presented "CT of Acute Renal Infections," "CT Staging of Renal Cancer," "The New Contrast Material: Issues and Answers," "Bladder and Prostate Oncologic Imaging," and the postgraduate course "Practical Radiology: 1989" at the University of British Columbia, Vancouver, February 5-10. As co-moderator of the First International Ioversol Symposium, McClellan presented "Summary of Worldwide Intravenous Clinical Data on Ioversol-320 (Optiray)" and "Use of Ioversol in Body and Head CT," Scottsdale, Arizona, February 23-25. He presented "Early Results with Biliary Lithotripsy on the Lithostar" at the Symposium on Biliary Lithotripsy, Hospital of University of Pennsylvania, March 2-3. McClellan was featured speaker at the Texas Radiological Society meeting, Galveston, April 6-9.

FYI

VISITING PROFESSORS & INVITED LECTURERS

Continued from page 23

Tom R. Miller, M.D., Ph.D., associate professor of radiology, presented "Advanced SPECT Filtering" at the SPECT Symposium, Society of Nuclear Medicine, New Orleans, February 13-14.

William A. Murphy, M.D., professor of radiology, presented "Musculoskeletal MRI: A General Overview," "Radiologic Pathophysiology of Synovial Arthropathy," and "The Temporomandibular Joint" at the continuing medical education course "Rheumatology for the Primary Care Physician" sponsored by Washington University School of Medicine, Copper Mountain, Colorado, January 14-19. Murphy also presented "Phlebography Using Optiray (Ioversol)" at the first International Ioversol Symposium: A Clinical Summary" sponsored by Mallinckrodt, Inc., Scottsdale, Arizona, February 23-25. As visiting professor, Murphy presented "MRI of Bone Marrow," "Pathophysiology of Inflammatory Arthritis," and "Forensic Radiology" at Columbia-Presbyterian Medical Center, New York City, March 15-16.

Gilbert H. Nussbaum, Ph.D., associate professor of radiation physics in radiology, presented a paper entitled "Hydralazine Enhanced Heating of Deep-Seated Canine Tumors" and was invited panelist and speaker in the workshop entitled "Advancing Hyperthermia Through Cooperation Between the Research Community and System Manufacturers" at the annual meeting of the Radiation Research Society and the North American Hyperthermia Group, Seattle, March 18-23.

Carlos A. Perez, M.D., professor of radiology and director of the Radiation Oncology Center, spoke on "Radiotherapy of Head and Neck Cancer," "Non-Conventional Fractionation in Radiotherapy," and "Radiotherapy of Central Nervous System Tumors" at the Second Ibero-American Oncology Congress, Bahia, Brazil, October 9-14. He presented "Radiation Therapy in Carcinoma of the Uterine Cervix," "Management of Early Carcinoma of the Breast," "Carcinoma of the Lung," "Radiation Therapy in Head and Neck Cancer," and "Multidisciplinary Management of Cancer" at the Congreso Internacional "Bodas de Oro Sociedad Peruana de Radiologia" in Lima, Peru, November 7-11. He spoke on "Radiation Therapy of Carcinoma of the Ovary," "Carcinoma of the Prostate," "Hyperthermia and Irradiation in the Treatment of Malignant Tumors," and "Treatment Planning Utilizing Computed Tomography" at the Third Reunion Nacional de Medicos Radioterapeutas,

Puebla, Mexico, November 22-26. He presented a talk on "Hyperthermia" at the American Cancer Society Ohio Cancer Symposium, Cincinnati, October 20.

Stuart S. Sagel, M.D., professor of radiology, spoke on "CT of the Mediastinum with MRI Correlation" and "Digital Radiography of the Chest" at the Thoracic Radiology Society Meeting, San Diego, March 5-9. He presented "CT of the Mediastinum with MRI Correlation," "CT of the Pericardium," and "Role of CT in the Evaluation of Bronchogenic Carcinoma" at the "Cutting Edge" Body CT Course, Bal Harbor, Florida, March 9-12.

Joseph R. Simpson, M.D., associate professor of radiology, presented "Brachytherapy of Brain Tumors: Washington University Experience" at the Memorial Sloan Kettering Cancer Center, New York, February 23-24.

Michael W. Vannier, M.D., associate professor of radiology, presented "Medical 3-D Image Reconstruction" at the annual meeting of the American Association for the Advancement of Science, San Francisco, January 14-19. He also presented "Validation of Magnetic Resonance Imaging (MRI) Multispectral Tissue Classification" at the 9th International Conference on Pattern Recognition, Rome, Italy, November 14-17. As invited chairman and lecturer at the Eidomatica Del Distretto Cranio Maxillo Facciale, Vannier spoke on "Our Experience with 3D CT and Preoperative Simulation," Milan, Italy, October 26-27.

Jerold W. Wallis, M.D., assistant professor of radiology, presented "Three-Dimensional SPECT Display" at the SPECT Symposium, Society of Nuclear Medicine, New Orleans, February 13-14.

Todd H. Wasserman, M.D., professor of radiology, was visiting professor at University of Iowa, Iowa City, December 8-9

SYMPOSIA

RADIOLOGICAL SOCIETY OF NORTH AMERICA

The following Mallinckrodt Institute staff members participated in the 74th Annual Scientific Assembly and Annual Meeting of the Radiological Society of North America, Chicago, November 27-December 2.

REFRESHER COURSES

Dixie J. Anderson, M.D., moderator; **Barbara Monsees, M.D.**; **Ronald G. Evens, M.D.**, "Patient-Initiated Mammography: The Potential and the Problems"

Mokhtar H. Gado, M.D., "Principles of Interpretation of MRI of the Brain"

Jay P. Heiken, M.D., "CT of the Retroperitoneum"

William A. Murphy, M.D., "Musculoskeletal System" during the Categorical Course in Magnetic Resonance Imaging

Carlos A. Perez, M.D., "Carcinoma of the Uterine Cervix"

FYI

APPOINTMENTS/ ELECTIONS

Stuart S. Sagel, M.D.,
"How to Deliver a Proper
Audiovisual Presentation"

Michael W. Vannier, M.D.;
Louis A. Gilula, M.D.;
John H. Harris, Jr., M.D.;
Elliot K. Fishman, M.D.,
"Three-dimensional Imag-
ing of the Musculoskeletal
System"

SCIENTIFIC SESSIONS

William A. Murphy, M.D.,
chaired the Skeletal Pro-
gram Subcommittee and
moderated the Bone Tumor
Scientific Session.

Michael W. Vannier, M.D.;
Fernando R. Gutierrez,
M.D.; **Charles E. Canter,**
M.D.; **Roberta L. Yoffie,**
R.T.; **Charles F. Hildebolt,**
D.D.S., Ph.D., "Evaluation
of Congenital Heart Disease
by Three-dimensional MR
Imaging"

Michael W. Vannier, M.D.;
Charles F. Hildebolt,
D.D.S., Ph.D.; **Jeffrey L.**
Marsh, M.D.; **Carolyn J.**
Offutt, R.T.; **Robert H.**
Knapp, B.M., R.T.; **Mok-**
htar H. Gado, M.D.; **T. A.**
Giordano, B.S.; **Robert**
Drebin, B.S.; **M. Mantle,**
B.S., "Determination of
the Diagnostic Value for
Three-dimensional CT
Reconstruction of the Head"

Michael W. Vannier, M.D.;
Charles F. Hildebolt,
D.D.S., Ph.D.; **Louis A.**
Gilula, M.D.; **Charles J.**
Sutherland, M.D.; **Carolyn**
J. Offutt, R.T.; **Robert**
Drebin, B.S.; **M. Mantle,**
B.S.; **T.A. Giordano, B.S.**,
"Evaluation of Diagnostic
Quality in Musculoskeletal
Three-dimensional CT
Scans"

WORKS IN PROGRESS

Judy M. Destouet, M.D.;
Barbara Monsees, M.D.;
John O. Eichling, Ph.D.;
V. Leroy Young, M.D.;
Cesar A. Gumucio, M.D.,
"Is a Radiolucent Breast
Implant Needed?"

MISSOURI SOCIETY OF RADIOLOGIC TECHNOLOGISTS

The following Mallinckrodt
radiology students and
staff members participated
in the 56th Annual Meeting
of the Missouri Society of
Radiologic Technologists,
Columbia, Missouri,
October 26-29.

ESSAY COMPETITION

Carol Meagher, senior
radiology student, received
first prize for "Dynamic
Radionuclide Studies Used
in Documenting Gastroin-
testinal Function."

EXHIBIT COMPETITION

Paul Becker, R.T., and
Michael Kleinhoffer, R.T.,
received the first place
award in the graduate tech-
nologist category for "Radi-
ography: Providing Vision
for the Physician."

Lori Brooks, Cristine
Collier and Julia Seper,
senior radiology students,
submitted "Arthrography:
A Joint Effort."

Barbara Gallion, Michelle
Marlow and Michelle
Robart, senior radiology
students, received third
prize for "Catch the Wave
with the Color Flow Doppler."

James Naes and Gilbert
Idowu, senior radiology
students, received first
prize for "Computerized
Radiography."

Paul Becker, R.T., staff
technologist, was elected
District Representative for
the Fourth District.

Cynthia Daniels, B.S.,
R.T., senior staff technolo-
gist and clinical instructor,
was elected secretary.

R. Gilbert Jost, M.D.,
professor of radiology, was
appointed Associate Editor
of *Digital Imaging*. Jost
has been elected to the
Board of Directors of the
Radiology Information Sys-
tem Consortium, an organi-
zation to promote the
development of computer
applications in radiology.

HONORS/ AWARDS

Jay P. Heiken, M.D.,
associate professor of radi-
ology, received the 1988
Editor's Recognition Award
with Distinction from
Radiology.

Michael W. Vannier, M.D.,
associate professor of radi-
ology, received a Certifi-
cate of Merit for placing
second in the Junior Clini-
cal Category of the 1988
Scholarship Contest spon-
sored by the Plastic Surgery
Educational Foundation.

Bruce L. McClelland,
M.D., professor of radiol-
ogy, has been appointed to
the Committee on Drugs
and Contrast Media and
reappointed to the Commit-
tee on Magnetic Resonance
Education and Training
and the Committee on Mar-
keting of the American Col-
lege of Radiology. He was
appointed vice-chairman of
the Faculty, Genitourinary
Radiology and the Inter-
society Commission of the
American College of
Radiology.

Patrick R. M. Thomas,
M.D., associate professor of
radiology, was appointed a
member of the National
Cancer Institute Extramural
Board for Physicians Data
Query Services.

John Wai-Chiu Wong,
Ph.D., assistant professor
of radiation physics in radi-
ology, was elected a repre-
sentative of a six-member
task group of the American
Association of Physicists in
Medicine to evaluate and
recommend "Tissue
Inhomogeneity Corrections
for Photon Beams."

FYI

TECHNOLOGIST NEWS

Donald R. Bernier, C.N.M.T., R.T., chief technologist, has been reappointed a member of the Committee on Nuclear Medicine Technology of the Commission on Human Resources, American College of Radiology.

Sharon Albertina, R.T., technical supervisor, was reappointed a Technologist Representative to Mallinckrodt's Radiography Program Advisory Committee for 1989.

Lori Brooks, senior radiography student, was appointed Student Representative to Mallinckrodt's Radiography Program Advisory Committee for 1989.

Cynthia K. Daniels, R.T., B.S., was promoted to the position of Assistant Program Director in Radiography effective March 1.

Jo Ann Johnson, A.R.T., medical coder, was elected secretary of the Missouri State Tumor Registrars Association.

Michael Kleinhoffer, R.T., special procedures technologist, was appointed Technologist Representative to Mallinckrodt's Radiography Program Advisory Committee for 1989.

Johnnie B. Moore, R.T., B.S., was promoted to the position of Radiography Program Director effective February 1.

Pat Sheeley Piatchek, A.R.T., assistant coordinator for medical records, was elected parliamentarian of the Missouri State Tumor Registrars Association.

Michael D. Ward, R.T., M.Ed., chief technologist and director of technical education, has entered the Ph.D. program in academic administration at St. Louis University.

CIC NEWS

The Cancer Information Center is cosponsored by the Mallinckrodt Institute of Radiology and the Barnard Free Skin and Cancer Hospital at the Washington University Medical Center.

CONTRIBUTIONS

Dr. and Mrs. Earl E. Shepard in memory of Mrs. Roy Gross

Mr. and Mrs. Kenrick Jones in memory of Mrs. Miriam Rose

Mr. and Mrs. Ben Cohen in memory of Sophia Crystal

Mr. and Mrs. David E. Bret in memory of Michael Bret

Rennie De Penaloza in memory of Connie Foley

Mr. and Mrs. James Grevas in memory of Louis Shiska

Theresa Cissell and Mr. and Mrs. Tom Burkhart in memory of Ann Wurth

Marguerite C. Schneider in memory of Richard J. Dammkoehler

Joan Harlan

Sara Winburn and Joe Nearn in memory of Houston Baxter Winburn

Vina S. Eggers and Samuel and Melba Eggers in memory of Houston Baxter Winburn

Margaret Sachs

Mr. and Mrs. Steve Collison in memory of Eleanor Sipes

Mr. and Mrs. David Morotz, Erican and Bryan in memory of Henry Hennenhoefler

Robert Blatz and family in memory of William J. Blatz

Mr. and Mrs. Louis Clark in memory of Judy Reedy

Kirkwood Lodge #484 A.F. & A.M. in memory of Maurice C. White

Elizabeth Szczepan in memory of Lowell Stambaugh

Judith R. Hanners in memory of Ruth Collier

Mary T. Kessler in memory of Ruth Collier

Dorothy M. Kampe in memory of Ruth Collier

Mr. and Mrs. Russell Pfeifle in memory of Howard Pickering

The Staff of Salon Christa in memory of Ben Smith

Mr. and Mrs. Odell Frye in memory of Vincent Hable

Betty Meeks in memory of Ann Wurth

Laurie A. Walters in memory of Ann Wurth

Linda M. Bober in memory of Ann Wurth

Frederick Hermann

Margaret A. Kiefer

Mr. and Mrs. Gary Rosenthal in memory of Sue Brotherton

Neal J. and Joan P. Farrell Foundation

Virginia and Edwin Wheeler in memory of Kristen Dietz

Mr. and Mrs. F. A. Hermann in memory of Louis Hager

Ceiling Components and Inplant Offices in memory of Delbert Inman

Crestwood-Sunset Hills Welcome Wagon in memory of Kay Smith

Sylvia Schachter in memory of Anna Dubinsky

Defense Contract Audit Agency McDonnell Aircraft Company in memory of Laura E. Andre

Mrs. Edward J. Schnuck in memory of Barbara A. O'Leary

CALENDAR

April 6-9, 1989

Texas Radiological Society Galveston, Texas

April 15-19, 1989

American Radium Society Annual Meeting St. Thomas, U.S. Virgin Islands

April 23-26, 1989

Second International Biliary Lithotripsy Symposium Vancouver, British Columbia

April 23-26, 1989

Digital Radiology and Networking Conference Kansas City, Missouri

FYI



Mallinckrodt Institute's eighth floor is being transformed into an interventional radiology center more comprehensive than any that exists anywhere else in the country. Workers have carefully laid down lead shielding in the floor, and soon after these photos were made, the walls went up.

Steve Kohler

May 6-12, 1989
American Roentgen Ray Society
New Orleans, Louisiana

May 21-23, 1989
American Society of Clinical Oncology
San Francisco, California

May 21-25, 1989
37th Annual Meeting of the Association of University Radiologists
Seattle, Washington

May 26, 1989
Probststein Oncology Lecture
Mallinckrodt Institute of Radiology
St. Louis, Missouri

June 5-10, 1989
American Board of Radiology Oral Examination
Louisville, Kentucky

June 12-16, 1989
1989 NAHG Hyperthermia School
St. Louis, Missouri

June 13-16, 1989
Society of Nuclear Medicine
St. Louis, Missouri

June 27-30, 1989
Gilbert H. Fletcher Society
Boston, Massachusetts

July 2-7, 1989
International Congress of Radiology
Paris, France

July 16-18, 1989
Radiation Therapy Oncology Group
Philadelphia, Pennsylvania



Steve Kohler

SPOTLIGHT

ARLETA DOUGLAS

Arleta Douglas owns what may be the world's only \$800 beagle. When she first came to know the dog, it was being mistreated by its owners, and Arleta resolved to rescue it despite the \$200 price placed on the little dog. Once Arleta had saved the pup, it immediately needed \$600 worth of veterinary care. Now the beagle is a beloved member of the Douglas household, just as Arleta had planned.

That story is not to suggest that Arleta is a spendthrift. Just the opposite is true; she's a careful guardian of the pursestrings. The point is that once she's committed to a goal, she's committed 100 percent. On behalf of Mallinckrodt Institute of Radiology, that commitment over the past quarter century has been to watch over the Institute's finances.

"Some people say it takes too much time and costs more than you save to straighten out a small error on a purchase order. But I don't feel that way," she says, revealing the origin of her reputation as a straight-talker. "I fight to get a credit as if it were money out of my own pocket." She declines to comment further but leaves the clear impression that there have been some gloves-off battles during her tenure.

Arleta learned her business style from her friend and mentor, Ginny Mueller, whom she calls "the best teacher and one of the most organized people I've ever known." Organization is a quality much prized by Arleta, since nothing gets ordered for the Institute or paid for unless the paperwork first crosses her desk.

Ginny retired from Mallinckrodt Institute a year ago, and now Arleta is leaving after 24 years. "There comes a time when you know you should leave," she says. Mixed emotions



Steve Kohler

accompany her departure, which will mean more time for personal matters but less contact with the friends she's made over the years.

During her work here, change at the Institute has accelerated. When she began in September, 1965, she had no job description and no specific tasks. The style was looser and more spontaneous. "We were a family of about a hundred and fifty people. Everybody knew all about everybody else, and we helped each other with problems," Arleta says. Now, an unavoidable distance has set in as a function of the Institute's size, though Arleta still thinks of many of her coworkers as family. "It's just that the family is getting so big."

Changes in organization have given her too many titles to recall, and she's not the sort to be impressed by labels. Even now she's not sure of the name of her position. "I think I'm an assistant departmental accountant, but I'd have to look it up."

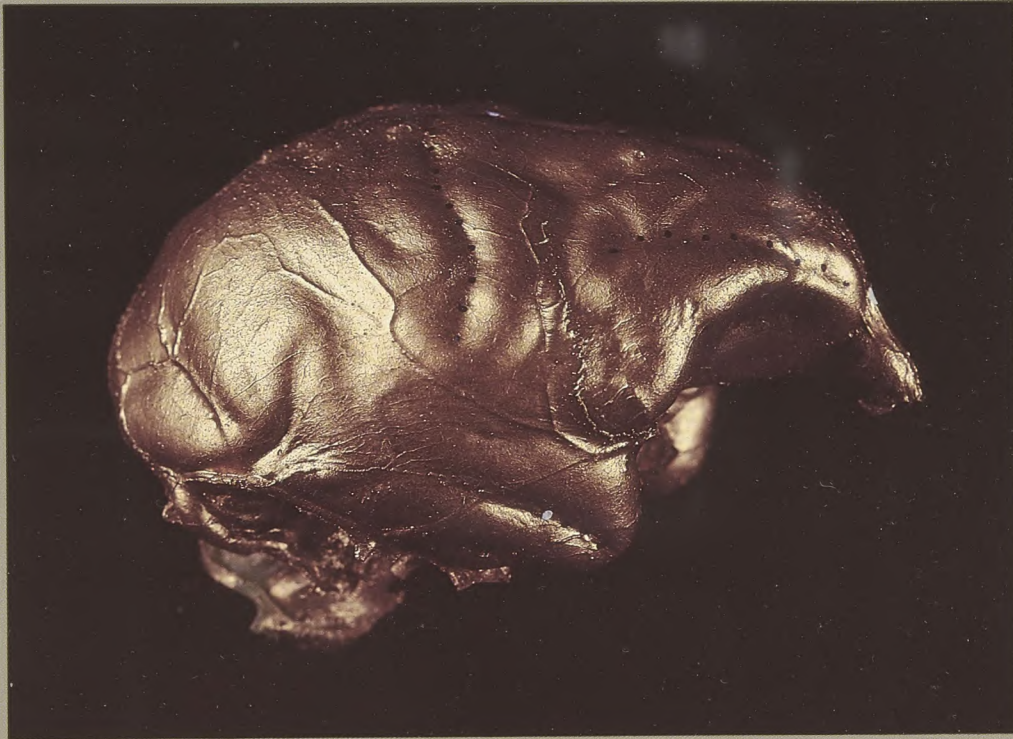Arleta came to Washington University for work after she and her partner sold a dress shop they'd started. She took a position as the first paid cashier in the Wishing Well gift shop—a job offered her by Edgar Monsanto

Queeny when he was a patient in Barnes Hospital. She also put in time as a nurse's aide, a "floater" helping out in the various clinics, and an employee in Nuclear Medicine before beginning her long employment in Mallinckrodt's executive offices.

Arleta's happy experiences have rubbed off on others. Three of her four children work in hospital or university settings, including daughter Suzie, who serves as administrative secretary to Armand Diaz, assistant professor of technical administration, and son Elery, manager of student housing for Washington University Medical Center. Husband Woody comes out of retirement every year to work at his trade of plumbing for Mallinckrodt Institute.

Her advice to her children and others coming along behind her: "Hold your tongue. Prove yourself by doing the best job you can. You'll be rewarded." That thinking has guided Arleta and shown its value at Washington University, where she says everyone has a chance to better himself.

Part of Arleta's reward for long service comes in her relationship with the University and its people; another part will come in retirement. She leaves on March 31 to spend more time with Woody as they care for their 10-room house, tend a big vegetable garden, and get in some fishing—maybe on the clear Ozark streams that run near Arleta's home town of Ellington, Missouri. She also plans to devote some of each day to reading, a passion she's been preparing to satisfy by putting aside interesting books until she has time to savor them. "I read everything...fiction, nonfiction, just about anything. But once I start one, I never put it away unfinished. I read every one to the very end." □



Steve Kohler

This latex endocast, made from the skull of a rhesus macaque, is one of the 400 providing insight into the heritability of brain features in higher primates. The population of Old World monkeys—isolated on Cayo Santiago off Puerto Rico—has been followed since the 1960s, with genealogies carefully recorded. From the endocasts of macaques that have died, configurations of the cerebral cortexes have been digitized in Mallinckrodt Institute of Radiology's image processing laboratory. The black dots visible in this photograph trace the brain sulci recorded in the computer. This research indicates that many brain characteristics are as heritable as osteological features. The study leads to investigation of the heritability of brain features in humans.

FOCAL SPOT

MALLINCKRODT INSTITUTE OF RADIOLOGY

MALLINCKRODT
INSTITUTE
OF RADIOLOGY
AT WASHINGTON UNIVERSITY MEDICAL CENTER

Director, Mallinckrodt Public Relations
Executive Editor
Michael Gold

Managing Editor
Steve Kohler

Associate Editor
Vicki Kunkler

Administrative Assistant
Marla Means

Design
Cunningham/Purviance
Marketing Communications

Contributing Writers
Vicki Kunkler
Marla Means

Photographers
Steve Kohler
Norman Hente
Thomas Murry

Focal Spot magazine is published three times a year by the Mallinckrodt Institute of Radiology at the Washington University Medical Center at 510 South Kingshighway, St. Louis, MO 63110.

Permission is granted to reproduce articles contained herein, provided **Focal Spot** magazine of the Mallinckrodt Institute of Radiology at the Washington University Medical Center is credited.

Public Relations Department
Mallinckrodt Institute of Radiology
510 South Kingshighway
St. Louis, MO 63110
(314) 362-2866.

Address Correction Requested

Non-Profit Organization
U.S. Postage
PAID
St. Louis, Missouri
Permit No. 1032



Steve Kohler